

# The Protective Effect of Kentut Leaf Extract (*Paederia foetida* L.) on Gastric Histopathology in *Escherichia coli*-Infected Sepsis Mice Model

Lisa Savitri\*, Elfred Rinaldo Kasimo

Department of Medical Laboratory Technology, Faculty of Health Sciences, Kadiri University,  
Jalan Selomangleng No. 1, Kediri, East Java, Indonesia.

Corresponding author\*

lissavitri@unik-kediri.ac.id

Manuscript received: 02 April, 2024. Revision accepted: 20 May, 2024. Published: 26 June, 2024.

## Abstract

Sepsis, a severe medical condition, signifies the systemic immune response to infection, often leading to organ dysfunction and mortality. *Escherichia coli* is a significant contributor to sepsis cases, particularly in gastrointestinal disorders. This study aimed to investigate the histopathological changes in the gastric tissue of mice induced by *Escherichia coli* infection and evaluate the protective effects of kentut leaf extract (*Paederia foetida* L.). Histopathological analysis revealed distinct alterations in the gastric tissue among different treatment groups. While normal mouse treatment showed no significant changes, negative control (K-) and positive control (K+) groups exhibited inflammation and hyperemia of the gastric mucosa, characterized by necrosis, degeneration, and inflammatory cell infiltration. Treatment with kentut leaf extract (P1, P2, and P3) resulted in milder inflammation compared to controls, indicating a protective effect against gastric mucosal damage induced by *Escherichia coli* infection. This protective mechanism is attributed to the anti-inflammatory properties of saponins, flavonoids, and essential oils present in kentut leaf extract. These findings underscore the potential therapeutic benefits of kentut leaf extract in mitigating gastric mucosal injury associated with bacterial infection.

**Keywords:** protective effect; kentut leaf extract; gastric histopathology; *Escherichia coli*; sepsis.

**Abbreviations:** basic sodium hydrogen phosphate ( $\text{Na}_2\text{HPO}_4$ ), mediated through mitogen-activated protein kinase (MAPK), microphthalmia-associated transcription factor (MITF), nitric oxide (NO), physiologic zur (PZ), tumor necrosis factor (TNF).

## INTRODUCTION

Sepsis is a medical emergency condition that depicts the systemic immune response of the body to an infection process, which can lead to end-stage organ dysfunction and death (Gyawali et al., 2019). In 2017, the largest contributors to sepsis cases and sepsis-related deaths across all ages were diarrheal diseases (9.2 to 15 million cases per year) and lower respiratory tract infections (1.8-2.8 million per year). One of the serious threats causing sepsis is *Escherichia coli* bacteria (Lawn et al., 2017; Stoll et al., 2011). Bacterial-induced sepsis is a life-threatening condition that arises when the body's response to infection injures its tissues and organs (Singer et al., 2016). The prevalence of *E. coli* bacterial infection causing gastrointestinal disorders in humans has increased (Silaban, 2021). *E. coli* is one of the most frequently isolated bacteria in the bloodstream and is the most commonly isolated Gram-negative bacterial infection in adult patients with bacteremia (Mora-Rillo, et al., 2015). The primary infection sites associated with sepsis are the respiratory/lung system (43%), urinary system (16%), abdomen (14%), head, which is associated

with fever of unknown origin (14%), and other locations/causes (13%) (Vakkalanka et al., 2018; Angus et al., 2013).

From a pathogenetic standpoint, sepsis is currently considered the result of several mechanisms simultaneously involving various pro-inflammatory and anti-inflammatory mediators (Piechota et al., 2007). Additionally, recent cellular modifications associated with sepsis have been defined, and the importance of microcirculation has been emphasized in the development of sepsis into septic shock (Ince, 2005). In this context, the endothelium has been identified as the fundamental functional unit in the pathophysiology of sepsis due to its role in regulating microcirculation and modulating coagulation mechanisms as well as inflammatory and anti-inflammatory signaling processes (Wolinsky, 1980; Belousoviene et al., 2021). The glycocalyx is a component of the endothelial membrane consisting of proteoglycans and glycoproteins. It mediates various functions, such as forming a mechanical barrier regulating vascular permeability, leukocyte activation and platelet adhesion, as well as modulating inflammatory/anti-inflammatory responses.

Damage to the morphofunctional integrity of the glycocalyx (known as "glycocalyx shedding") can occur due to oxidative agents, cytokines, bacterial exotoxins, and endotoxins. This event leads to leukocyte diapedesis and increased vascular permeability with edema production, which increases interstitial pressure and worsens tissue perfusion (Kaukonen et al., 2015). Several organs that are likely to experience dysfunction are the gastric.

In sepsis, the inflammatory response to attacking pathogens involves inflammatory and anti-inflammatory processes, humoral and cellular reactions, and circulatory abnormalities (Bhattacharjee et al., 2017). In the early phase after injury, the inflammatory response is initiated by acute-phase reactants or proinflammatory factors (Le et al., 1987). The occurrence of increased reactive oxygen and accumulation of oxidative stress leads to a decrease in nitric oxide (NO), reducing NO bioavailability in coronary and peripheral circulation, thus causing vascular dysfunction correlated with increased risk of organ dysfunction leading to death (Kaukonen et al., 2015). As important inflammatory factors, tumor necrosis factor (TNF) causes fever, hemodynamic abnormalities, anorexia, joint pain, and neutrophil aggregation, which are considered typical symptoms associated with sepsis (Kumari et al., 2017). Therefore, it is crucial to explore the potential role of inflammatory factors in the pathophysiology of sepsis. Moreover, eliminating the concept of SIRS from sepsis will certainly lead to continuous issues regarding basic research and clinical management of sepsis.

Despite all experimental and clinical research efforts over the last three decades, the ability to influence the course of bacteria remains limited. Immunotherapy-based therapies have mostly proven ineffective so far (Saifudin, 2014). Hence, actions more geared towards preventive measures are needed, particularly using herbal materials, as they are believed to have low side effects. One traditional plant believed by ancient communities to treat digestive disorders such as diarrhea is the kentut leaf (*Paederia foetida* L.), known in East Java as 'daun sembukan'. Kentut leaves contain secondary metabolites such as alkaloids, saponins, tannins, and flavonoids that pharmacologically have benefits such as antioxidants, antibiotics, anticancer agents, insect repellents, antitumor agents, and immunomodulatory agents (Abriyanto et al., 2012; Chanda et al., 2015; Ramadhan et al., 2021; Savitri, et al., 2023).

Many of the compounds isolated from *kentut* leaves are bioactive and have been shown to have several bioactivities, such as anthraquinones with anthelmintic, antidiarrheal, anti-hyperglycemic, anti-hyperlipidemic, anti-inflammatory, antioxidant, antimicrobial, and antitussive properties (Savitri et al., 2023; Savitri and Kasimo, 2022; Wang et al., 2014; Soni et al., 2013). Although the strong unpleasant odor is mainly caused by the presence of several simple sulfur compounds (the

main one being dimethyl sulfide), sulfur-containing glycosides, such as paederoside, are also involved in its foul smell.

In recent years, the focus has shifted to more mechanistic studies, attempting to understand how extracts and pure compounds from kentut leaves lead to their pharmacological actions. Previous research has studied the antimelanogenic properties of this plant extract on murine melanoma cells and has shown that this effect is mediated through mitogen-activated protein kinase (MAPK) signaling via microphthalmia-associated transcription factor (MITF) downregulation (Trung et al., 2021). Similarly, other research has shown that this plant can induce anticancer activity by interfering with chromatin modification enzymes and altering the expression of proinflammatory cytokine genes in prostate cancer cells (Chung, 2021).

Pharmacological studies conducted on *kentut* leaves to date have provided some scientific evidence supporting their use in traditional medicine for the treatment of certain human diseases, and several possible mechanisms of action have also been demonstrated. However, there is little or no information available on well-designed, randomized, double-blind clinical studies with this plant. The need for extensive clinical studies to promote this plant or its components as modern drug formulations cannot be overlooked.

## MATERIALS AND METHODS

### Population and Sample

The population used in this study consisted of mice (*Mus musculus*). The sample used in this study comprised 30 male Balb/c mice aged 4-8 weeks with a weight of 20-30 grams obtained from the Veterinary Center Farma (Pusvetma), Surabaya, East Java.

### Tools and Materials

The tools used in this study included: Disposable syringe 1 mL, disposable syringe 3 mL, disposable syringe 5 mL, feeding tube size 35 cm, urine container 60 mL, vaculab EDTA K3 3 mL, eppendorf 2 mL, microcentrifuge, micropipette, freezer, rotary microtome or sliding microtome, brush, waterbath, object glass, eppendorf 1500  $\mu$ L, blue tips, yellow tips, white tips 10  $\mu$ L, tube 15 mL, tube 50 mL, surgical board, surgical instruments set (including scissors, forceps, and needle), gloves, tissue, mask, binocular light microscope, and microscope camera.

The materials used in this study included: male Balb/c mice aged 4-8 weeks with a weight of 20-30 grams, extract of *kentut* leaves (*Paederia foetida* L.), ciprofloxacin, clinical isolate (wild type) *E. coli* with a dose of  $1 \times 10^5$  CFU/mL, physiologic zur (PZ) (aqua pro injection free from pyrogen), mouse feed, wood powder (kawol), methanol, giemsa, distilled water, H<sub>2</sub>CO

(formaldehyde) 37% solution, basic sodium hydrogen phosphate ( $\text{Na}_2\text{HPO}_4$ ) 6.5 grams, distilled water 900 mL, formaldehyde 37-40%), ethanol 80%, ethanol 95%, absolute ethanol, xylene, clearing solution, paraffin, SA-HRP, BSA, HCl.

## Research Procedure

### Acclimatization of Mice

Male mice were weighed and placed in standard polypropylene cages with bedding using wood powder for acclimatization for two weeks. Cage bedding was changed every three days. Feed provided was softened with water first, then shaped into an elongated form, weighing approximately 5 grams. Water was provided ad libitum. Feed and water were replaced daily. Mice were divided into six treatment groups after acclimatization for two weeks.

### Treatment on Experimental Animals

Acclimatized mice were treated for 14 days with the following variations: 1) group 1 as normal control (N), consisting of mice not given gastric tube feeding, 2) group 2 as negative control (K-), consisting of mice given distilled water with a volume of 0.5 mL, 3) group 3 as positive control (K+), consisting of mice given ciprofloxacin at a dose of 500 mg/kg BW with a volume of 0.26 mL, 4) group 4 as treatment 1 (P1), consisting of mice given kentut leaf extract at a dose of 100 mg/kg BW with a volume of 0.5 mL, 5) group 5 as treatment 2 (P2), consisting of mice given kentut leaf extract at a dose of 300 mg/kg BW with a volume of 0.5 mL, 6) group 6 as treatment 3 (P3), consisting of mice given kentut leaf extract at a dose of 500 mg/kg BW with a volume of 0.5 mL.

### Sepsis Model Treatment in Mice

Mice that had been given treatment were injected intraperitoneally with *E. coli* at a dose of  $1 \times 10^5$  CFU/mL. Mice 24 hours post-exposure to polymicrobial sepsis will show sepsis events, so mice can be euthanized after 24 hours. If mice die before 24 hours, immediate surgery should be performed to remove the stomach and intestines to prevent autolysis. Organ slices taken are in the middle, left, and right edges.

### Tissue Processing

Gastric tissue were fixed in formalin buffer to maintain cell morphology as original to prevent autolysis and bacterial or fungal growth. The next step is to make paraffin blocks. After making the paraffin blocks, tissue sectioning was performed using a rotary microtome or sliding microtome with a thickness of 4-6 microns. The obtained sections were then taken with a brush moistened with water and placed on the surface of a waterbath. The expanded tissue was then taken with object glass coated with tissue adhesive, then dried at room temperature and placed in an oven overnight.

### Histopathological Observation of the Gastric

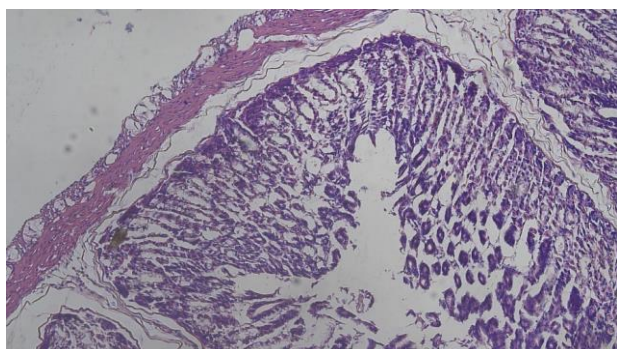
Histopathological observation of the mouse stomach and intestines involved preparing histological specimens by staining them with hematoxylin and eosin. The histopathological observation included checking for abnormal cells (cells undergoing differentiation, necrosis, and apoptosis). The calculation of abnormal cells was done by dividing the abnormal cells counted by all preserved cells, then multiplied by 100%, thus the data was expressed in percentage (%).

## RESULTS AND DISCUSSION

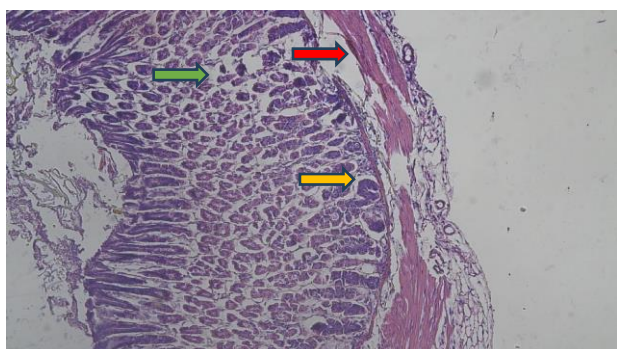
### Result

**Table 1.** Histopathological Characterization of Mice Gastric Tissue in a Sepsis Model Induced by *Escherichia coli* Infection.

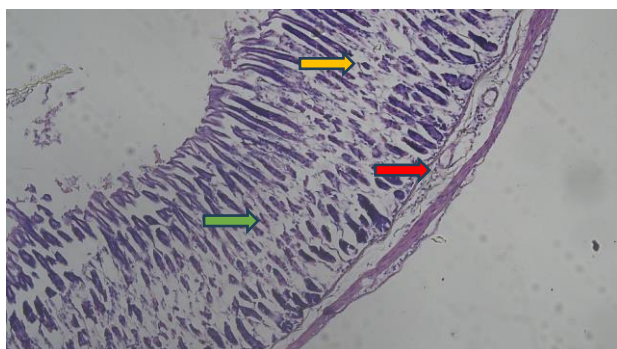
Group	Cell Degeneration		Necrosis		Infiltration of Inflammatory Cells	
	Average	SD	Average	SD	Average	SD
Normal	2.21%	0.02	2.44%	0.02	1.62%	0.02
Positive (+)	21.63%	0.02	17.20%	0.02	28.05%	0.02
Negative (-)	23.41%	0.04	21.55%	0.03	48.63%	0.05
P1 (100mg/kgBW)	20.79%	0.03	22.62%	0.04	39.56%	0.03
P2 (300mg/kgBW)	9.08%	0.02	6.05%	0.02	18.45%	0.03
P3 (500mg/kgBW)	7.72%	0.04	5.18%	0.02	16.07%	0.03



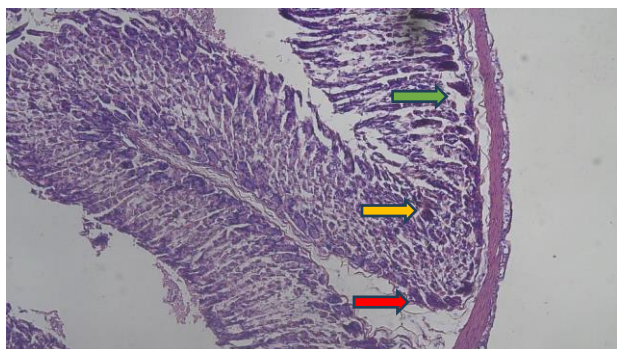
**Figure 1.** Histopathological Characterization of the Mice Gastric Treatment Normal Magnification of 400x



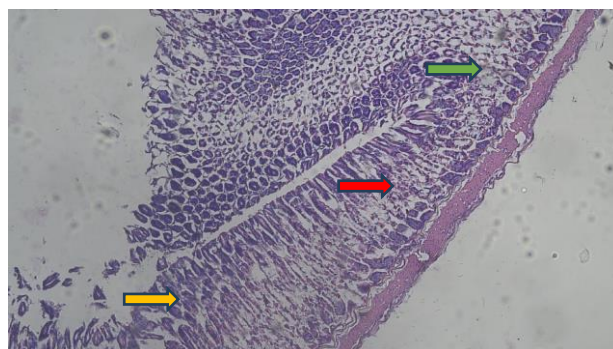
**Figure 2.** Histopathological Characterization of the Mice Gastric Treatment K- Magnification of 400x, Necrosis (Green Arrow), Degeneration (Yellow Arrow), and Infiltration of Inflammatory Cells (Red Arrow)



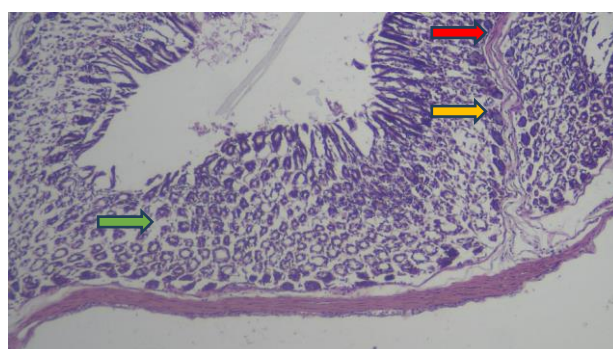
**Figure 3.** Histopathological Characterization of the Mice Gastric Treatment K+ Magnification of 400x, Necrosis (Green Arrow), Degeneration (Yellow Arrow), and Infiltration of Inflammatory Cells (Red Arrow)



**Figure 4.** Histopathological Characterization of the Mice Gastric Treatment P1 Magnification of 400x, Necrosis (Green Arrow), Degeneration (Yellow Arrow), and Infiltration of Inflammatory Cells (Red Arrow)



**Figure 5.** Histopathological Characterization of the Mice Gastric Treatment P2 Magnification of 400x, Necrosis (Green Arrow), Degeneration (Yellow Arrow), and Infiltration of Inflammatory Cells (Red Arrow)



**Figure 6.** Histopathological Characterization of the Mice Gastric Treatment P3 Magnification of 400x, Necrosis (Green Arrow), Degeneration (Yellow Arrow), and Infiltration of Inflammatory Cells (Red Arrow)

## Discussion

Based on the results of this study, it is known that normal mouse treatment (N) does not cause changes in the histopathological appearance of the gastric (**Figure 1**), whereas negative control treatment (K-), consisting of mice given distilled water with a volume of 0.5 mL, positive control treatment (K+), consisting of mice given ciprofloxacin at a dose of 500 mg/kg BW with a volume of 0.26 mL, treatment 1 (P1), consisting of mice given *kentut* leaf extract at a dose of 100 mg/kg BW with a volume of 0.5 mL, treatment 2 (P2), consisting of mice given *kentut* leaf extract at a dose of 300 mg/kg BW with a volume of 0.5 mL, treatment 3 (P3), consisting of mice given *kentut* leaf extract at a dose of 500 mg/kg BW with a volume of 0.5 mL resulted in inflammation and hyperemia of the gastric mucosa layer. The results of this study indicate changes in the histopathological appearance of the gastric tissue, where there are cells experiencing necrosis, degeneration, and infiltration of inflammatory cells as a result of *Escherichia coli* infection.

In the K- treatment (**Figure 2**), there is evidence of epithelial cells composing the gastric tissue experiencing necrosis and degeneration, as well as evidence of inflammatory cell infiltration. In the gastrointestinal system, a large amount of *E. coli* infection can lead to

peptic ulcers, where the observed irritation is the presence of epithelial cells composing the gastric tissue experiencing necrosis and degeneration, as well as evidence of inflammatory cell infiltration (Santi, 2013). Ulcers in the stomach are characterized by lesions on the gastric mucosa. Ulcers occur due to the imbalance of gastric acid-pepsin secretion and mucus (a product of gastric glands that functions as a barrier to the gastric lining), thus injuring the gastric mucosa. To overcome this, inflammation occurs, marked by the appearance of inflammatory cells aimed at repairing the injured gastric mucosa (Abdullah, 2008).

In the K+ treatment (**Figure 3**), there is evidence of epithelial cells composing the gastric tissue experiencing necrosis and degeneration, as well as evidence of inflammatory cell infiltration. Ciprofloxacin can cause shedding of surface epithelial cells of the stomach and reduce mucus secretion, which serves as a protective barrier against acid (Stickel, 1997). The potential occurrence of drug interactions is dominated by fluoroquinolone antibiotics and gastrointestinal drugs. The most common side effect of ciprofloxacin is gastrointestinal disturbance (2%), such as abdominal pain, nausea (4%-8%), vomiting, anorexia, and diarrhea (4%-5%). According to Gosal et al., (2012), mucosal defense damage occurs due to the local effects of ciprofloxacin. When antibiotics are in the stomach, which is acidic (pH less than 3), they will form particles that are non-ionized. Under such conditions, drug particles can easily diffuse through the lipid membrane into the gastric epithelial cells along with ions. Additionally, uncoupling of mitochondrial oxidative phosphorylation leading to decreased ATP production, increased AMP, and increased ADP can cause cell damage. These changes are followed by mitochondrial damage, increased formation of oxygen radicals, and changes in balance, thus reducing gastric mucosal resistance. This condition allows penetration of acid, pepsin, bile, and proteolytic enzymes from the gastric lumen into the mucosa, causing degeneration and even necrosis of cells.

In treatments P1, P2, and P3 (**Figures 4, 5, and 6**), there is evidence of epithelial cells composing the gastric tissue with mild inflammation compared to the K- and K+ groups. This indicates that *kentut* leaf extract has a protective effect on the stomach. The mechanism of gastric protection in the mouse sepsis model is thought to be due to the presence of saponin, flavonoids, and essential oils found in *kentut* leaf extract. The most likely mechanism of gastric protection is believed to be that saponins can interact with many lipid membranes, such as phospholipids that are precursors to prostaglandins and other inflammatory mediators (Savitri and Ihsan, 2020). Flavonoids also have anti-inflammatory mechanisms by inhibiting the activity of COX and/or lipoxygenase enzymes, as inhibition of the COX and lipoxygenase pathways can lead to inhibition of eicosanoid and leukotriene biosynthesis, which are end

products of the COX and lipoxygenase pathways. (Savitri, 2022). Additionally, flavonoids can reduce the number of non-migrating white blood cells and reduce complement activation, thus reducing white blood cell adhesion to endothelial cells and causing a decrease in the body's inflammatory response. Flavonoids also play a role in inhibiting histamine release. The anti-inflammatory effect of flavonoids is supported by their action as antihistamines (Savitri, et al., 2020). Histamine is one of the inflammatory mediators whose release is continued by calcium entry into cells.

Flavonoids can inhibit cAMP phosphodiesterase enzymes, thus increasing cAMP levels in mast cells, thereby preventing calcium entry into cells, which also inhibits histamine release. Flavonoids can also stabilize Reactive Oxygen Species (ROS) by reacting with reactive radical compounds, making the radicals inactive (Savitri, et al., 2019). This study is also supported by previous research conducted by Savitri and Kasimo (2022) on preventive tests for IL-6 levels in a mouse sepsis model induced by *E. coli*, which found that *kentut* leaf extract at a dose of 500 mg/kg BW (P3) was most effective in reducing IL-6 levels. The anti-inflammatory mechanism in sepsis is thought to be caused by the presence of saponins, flavonoids, and essential oils found in *kentut* leaf extract. The most likely anti-inflammatory mechanism is thought to be caused by saponins that can interact with many lipid membranes, such as phospholipids that are precursors to prostaglandins and other inflammatory mediators.

## CONCLUSIONS

The study reveals distinct histopathological changes in the gastric tissue of mice subjected to different treatments. Normal mouse treatment (N) did not induce any significant alterations in gastric histopathology. However, negative control treatment (K-), involving distilled water administration, and positive control treatment (K+), involving ciprofloxacin administration, both led to inflammation and hyperemia of the gastric mucosa, characterized by necrosis, degeneration, and inflammatory cell infiltration. The observed effects are consistent with the known gastrointestinal disturbances associated with ciprofloxacin administration. Additionally, the study demonstrated that treatment with *kentut* leaf extract (P1, P2, and P3) resulted in milder inflammation compared to the negative and positive control groups. This suggests a protective effect of *kentut* leaf extract against gastric mucosal damage induced by *Escherichia coli* infection. The protective mechanism is attributed to the presence of saponins, flavonoids, and essential oils in the *kentut* leaf extract, which exhibit anti-inflammatory properties by inhibiting inflammatory enzyme activity, reducing white blood cell adhesion, and stabilizing reactive oxygen species. Overall, these findings highlight the potential therapeutic benefits of

*kentut* leaf extract in mitigating gastric mucosal injury associated with bacterial infection.

**Acknowledgements:** The author would like to thank the Institute for Research, Development, and Community Service (LP3M) of Kadiri University and Ministry of Education, Culture, Research, and Technology Directorate General of Vocational Education, Indonesia which has always provided support for writing and publications.

**Authors' Contributions:** Lisa Savitri designed the study, analyzed the data, and wrote the manuscript. Elfred Rinaldo Kasimo wrote the manuscript. All authors read and approved the final version of the manuscript.

**Competing Interests:** The authors declare that there are no competing interests.

**Funding:** This research was funded by the Ministry of Education, Culture, Research, and Technology Directorate General of Vocational Education, Indonesia under the main contract number 104/SPK/D.D4/PPK.01.APTV/III/2024 and derivative contract numbers 004/SP2H/PPKM-PTV/LL7/2024, 05/P.1/LP3M/I/2024.

## REFERENCES

- Abdullah. (2008). Ilmu Penyakit Dalam (Internal Medical Disease). Medan: Universitas Sumatera Utara. Stickel F. 1997. Effect of Vitamin E Supplementation on Prostaglandin Concentrations in Aspirin-Induced Acute Gastric Injuring Aged Rats. *Am J Clin Nutr*, 66: 1218-1223.
- Abriyanto, AE., Sabikis, Sudarso. (2012). Aktivitas Antifungi Ekstrak Etanol Daun Sembukan (*Paedaria foetida* L) terhadap *Candida albicans*. *Pharmacy*, Vol 9 No 3, Desember 2012
- Angus, D.C.; van der Poll, T. (2013). Severe Sepsis and Septic Shock. *N. Engl. J. Med.* 2013, 369, 840–851.
- Belousoviene, E.; Kiudulaite, I.; Pilvinis, V.; Pranskunas, A. (2021). Links between Endothelial Glycocalyx Changes and Microcirculatory Parameters in Septic Patients. *Life* 2021, 11, 790.
- Bhattacharjee, P., D.P. Edelson, and M.M. Churpek. (2017). Identifying patients with sepsis on the hospital wards. *Chest* 151: 898–907.
- Chanda, S., Deb, L., Tiwari, R. K., Singh, K., Ahmad, S. (2015). Gastroprotective mechanism of *Paedaria foetida* Linn. (Rubiaceae) – a popular edible plant used by the tribal community of North-East India. *BMC Complement. Altern. Med.* 15, article number: 304.
- Chung, Y.C. (2021). Anti-melanogenic effects of *Paedaria foetida* L. extract via MAPK signaling-mediated MITF downregulations. *Cosmetics* 8, article number: 22.
- Gosal F, Paringkoan B, Wenas NT. (2012). Patofisiologi dan Penanganan Gastropati Obat Antiinflamasi Nonsteroid. *Jurnal Indonesia Medical Assoc*, 62(11): 444-449.
- Gyawali, B., Ramakrishna, K., & Dhamoon, A. S. (2019). Sepsis: The evolution in definition, pathophysiology, and management. *SAGE open medicine*, 7, 2050312119835043. <https://doi.org/10.1177/2050312119835043>
- Ince, C. (2005). The microcirculation is the motor of sepsis. *Crit. Care* 2005, 9 (Suppl. 4), S13–S19.
- Kaukonen K-M, Bailey M, Pilcher D, Cooper DJ, Bellomo R. (2015) Systemic inflammatory response syndrome criteria in defining severe sepsis. *N Engl J Med* 2015;372(17):1629–38.
- Kumari, Preeti, Chandrawati Kumari, and Poornima Shekhar Singh. (2017) "Phytochemical screening of selected medicinal plants for secondary metabolites." *Int. J. Life. Sci. Scienti. Res* 2017; 3(4):1151-1157. <https://doi.org/10.21276/ijlssr.2017.3.4.9>
- Lawn JE, Bianchi-Jassir F, Russell NJ, Kohli-Lynch M, Tann CJ, Hall J, et al. (2017) Group B Streptococcal Disease Worldwide for Pregnant Women, Stillbirths, and Children: Why, What, and How to Undertake Estimates? *Clin Infect Dis.* 2017;65(suppl\_2):S89-S99.
- Le, J., and J. Vilcek. (1987). Tumor necrosis factor and interleukin-1: cytokines with multiple overlapping biological activities. *Lab Invest.* 56: 234.
- Mora-Rillo M, Fernández-Romero N, Navarro-San Francisco C, Díez-Sebastián J, Romero-Gómez MP, Fernández FA, et al. (2015) Impact of virulence genes on sepsis severity and survival in *Escherichia coli* bacteremia. *Virulence.* 2015; (1):93-100.
- Piechota, M.; Banach, M.; Irzanski, R.; Barylski, M.; Piechota-Urbanska, M.; Kowalski, J.; Pawlicki, L. (2007). Plasma endothelin-1 levels in septic patients. *J. Intensive Care Med.* 2007, 22, 232–239.
- Ramadhan, A., Wardani, A.K., Dlamini, D.S., Chang, C.I. (2021). Anthraquinone derivatives and its antibacterial properties from *Paedaria foetida* stems. *Nat. Prod. J.* 11, 193-199. 23.
- Saifudin, Azis. (2014) *Senyawa alam metabolit sekunder teori, konsep, dan teknik pemurnian*. Deepublish, 2014.
- Santi DA. (2013). Efek Jus Buah Jambu Biji (*Psidium guajava* Linn) terhadap Gangguan Toleransi Glukosa pada Tikus Putih Jantan (*Rattus norvegicus*) Akibat Efek Samping Deksametason. *Calyptra: Jurnal Ilmiah Mahasiswa Universitas Surabaya*, 2: 1-19.
- Savitri, L., Sandhika, W., & Wahyu Widodo, A. D. (2019). Perbedaan Ekspresi Caspase 3 pada Limpa Tikus Model Sepsis yang Diinfeksi *Escherichia coli* ESBL dan dengan yang Diinfeksi *Klebsiella pneumoniae* Carbapenemase. *Prosiding Seminar Nasional Multidisiplin*, 2(1), 300–306. Retrieved from <https://ejournal.unwaha.ac.id/index.php/snami/article/view/705>
- Savitri, L. & Ihsan, K. (2020). Aktivitas Triterpenoid Kulit Batang Waru Jawa (*Hibiscus tiliaceus* L.) terhadap Bakteri *Escherichia coli*. *Jurnal Kesehatan Perintis (Perintis's Health Journal)*, 7 (1) 2020: 41-50.
- Savitri, Lisa; Maslikah, Siti & Susilowati,. (2020). Effect of red betel leaf extract (*Piper crocatum*) against interleukin-1 beta (IL-1 $\beta$ ) levels and thickness of feet oedema in *Mus musculus* (swiss strain) rheumatoid arthritis model. *AIP Conference Proceedings*. 2231. 040012. 10.1063/5.0002562.
- Savitri, Lisa. (2022). Perbandingan Tingkat Keganasan Bakteri Berdasarkan Lama Waktu Kematian pada Tikus Model Sepsis yang Diinfeksi *Escherichia coli* ESBL dan *Klebsiella pneumoniae* Carbapenemase. *Quagga: Jurnal Pendidikan dan Biologi*. 14. 67-72. 10.25134/quagga.v14i1.5065.

- Savitri, L., Kasimo, E.R. (2022). Efek Preventif Ekstrak Daun Kentut (*Paederia foetida* L.) Terhadap Kadar Interleukin-6 Pada Mencit Model Sepsis yang Diinduksi *Escherichia coli*. Indonesian Journal of Natural Science Education, 5(2): 38-43. DOI: <https://doi.org/10.31002/nse.v5i2.2778>
- Savitri, L., Kasimo, E.R., Krissanjaya, R. (2023). Rahasia Daun Kentut: Peran Profilaksis Pencegahan Sepsis. Nganjuk: CV. Dewa Publishing.
- Savitri, L., Tiyas, E.W., Freitas, M.D., Retnowati, A. (2023). Daun Kentut: Antibakteri Super dan Perlindungan Imun. Nganjuk: CV. Dewa Publishing.
- Silaban H. (2021) The Effect of Various Concentrations of Ethanol Extract of the Leaves of *Paederia foetida* L. on the Growth of *Escherichia Coli* Bacteria. JDDT. 11(6):61-7.
- Singer M, Deutschman CS, Seymour CW, Shankar-Hari M, Annane D, Bauer M, Bellomo R, Bernard GR, Chiche JD, Cooper-Smith CM, Hotchkiss RS, Levy MM, Marshall JC, Martin GS, Opal SM, Rubenfeld GD, van der Poll T, Vincent JL, Angus DC. (2016) The Third International Consensus Definitions for Sepsis and Septic Shock (Sepsis-3). JAMA. 2016 Feb 23;315(8):801-10.
- Soni, R.K., Irchhaiya, R., Dixit, V., Shashi, A. (2013). *Paederia foetida* Linn: Phytochemistry, pharmacological and traditional uses. Int. J. Pharm. Sci. Res.4, 4525-4530.
- Stoll BJ, Hansen NI, Sanchez PJ, Faix RG, Poindexter BB, Van Meurs KP, et al. (2011) Early onset neonatal sepsis: the burden of group B Streptococcal and *E. coli* disease continues. Pediatrics. 2011;127(5):817-26.
- Trung, N.Q., Thong, N.M., Cuong, D.M., Manh, T.D., Hoang, L.P., Hien, N.K., Nam, P.C., Quang, D.T., Mechler, A., Vo, Q.V. (2021). Radical scavenging activity of natural anthraquinones: A theoretical insight. ACS Omega 6, 13391-13397.
- Vakkalanka, J.P.; Harland, K.K.; Swanson, M.B.; Mohr, N.M. (2018). Clinical and epidemiological variability in severe sepsis: An ecological study. J. Epidemiol. Community Health 2018, 72, 741–745.
- Wolinsky, H. (1980). A proposal linking clearance of circulating lipoproteins to tissue metabolic activity as a basis for understanding atherogenesis. Circ. Res. 1980, 47, 301–311.
- Wang, L., Jiang, Y., Han, T., Zheng, C., Qin, L. (2014). A phytochemical, pharmacological and clinical profile of *Paederia foetida* and *P. scandens*. Nat. Prod. Commun. 9, 879-886.

**THIS PAGE INTENTIONALLY LEFT BLANK**