

# Liver Protection Effect of Red Rose Petal Methanol Extract in Copper-Induced Liver Injury in Male Wistar Rats

Caroline Febrina Hutagalung, Ermi Girsang\*, Maya Sari Mutia, Suhartina, Oliviti Natali

Faculty of Medicine, Dentistry, and Health Sciences, Universitas Prima Indonesia, Medan, Indonesia.

Corresponding author\*

ermigirsang@unprimdn.ac.id

Manuscript received: 21 July, 2023. Revision accepted: 12 August, 2023. Published: 13 September, 2023.

## Abstract

The human body requires low amounts of copper to maintain homeostasis, but high copper intake can cause various health problems. Many previous studies have been performed to look for natural products that can neutralize the excessive copper effect; one such natural product is a rose petal. Therefore, this study aims to investigate the liver protection effect of rose petals in copper-induced liver injury in male Wistar rats. This experimental study used thirty male Wistar rats that were grouped into five groups, including control, standard (quercetin), Rose Petal Methanol Extract-1 (400 mg/kg BW), 2 (800 mg/kg BW), and 3 (1,200 mg/kg BW). All groups were treated for 14 days, and all rats were given copper (II) sulfate suspension for the last three days. On the fifteenth day, all rats were sacrificed to obtain blood and liver tissue SGOT, SGPT, and liver histology study. The results showed that rose petal methanol extract significantly decreased SGOT and SGPT levels compared to the control group (P-value <0.05). The reduced area of ballooning degeneration and necrosis were in line with the increased dose of rose petal extract supported the liver protection effect of rose petal extract. Therefore, it can be concluded that rose petal methanol extract protects the liver against copper impacts.

**Keywords:** Copper; Rose; SGOT; SGPT; Liver Protection.

## INTRODUCTION

The industrial development is followed by increasing heavy metal pollution, especially water pollution. These heavy metals include lead, mercury, arsenic, aluminium, copper, nickel, tin, antimony, bromine, bismuth, and vanadium. These metals come from wastewater from some industrial activity. Copper, one of these heavy metals, comes from construction, airplanes and ships, roofing, plumbing, alloys of brass and bronze, home decoration, non-electrical industrial machinery, thermometer starter machine, and the agricultural machinery industry (Wilson, 2012).

Heavy metal pollution has become a national burden in some countries, including Indonesia. Some studies have reported the severity of this pollution. Chubaka et al. reported that several Water Tanks in the Adelaide Region, Australia, had been polluted by some heavy metal compounds. Most of these pollutants were lead, which had contaminated 47 rainwater tanks from 53 samples based on ADWG (Australian Drink Water Guidelines) threshold. Other heavy metal compounds detected in these rainwater tanks were zinc, cadmium, and copper, found in lower concentrations (Chubaka *et al.*, 2018). A similar condition is also found in India. Nizami and Rehman reported that the six highest concentrations of contaminated heavy metal in the Ganga

Rivers were Mn, Cr, Cu, Zn, Pb, and Fe. Furthermore, similar pollution also contaminated other rivers in India (Nizami and Rehman, 2018).

Indonesia also undergoes similar heavy metal pollution in some rivers. Septiono and Roosmini (2015) reported that chromium was the highest level of heavy metal pollution based on analysis from several sampling points of fish, water, and sediments of the Citarum River. Other heavy metal compounds at the sampling point were copper and cadmium (Septiono and Roosmini, 2015). On the other hand, Gafur et al. also reported that As, Hg, and Pb highly contaminated the Bone River, that 1000 to 10,000 times higher than the WHO standard drinking water. This pollution may be due to small-scale gold mining activities. (Gafur *et al.*, 2018).

Some heavy metal compounds have been reported to contaminate the water. One of these heavy metal compounds is copper. Copper is required at low levels in the human body to maintain homeostasis. However, higher copper intake can cause considerable organ damage, lipid metabolism, immune system, and nervous disorders. It is due to the formation of reactive oxygen species (ROS) and LDL modification to initiate atherogenesis by increasing macrophage transformation, vasoconstrictor, and prothrombotic (Wilson, 2012).

Some studies have been performed to look for natural products that potentially act as antioxidants to neutralize the effects of excess copper levels, which can stimulate ROS formation. One of these natural products is a rose petal that has been widely studied. Boskabady *et al.* 2011 reported the pharmacological effects of rose petals, including hypnotic, analgesic, anticonvulsant, anti-tussive, antibacterial, anti-diabetic, laxative, anti-inflammatory, antioxidant, and bronchodilator. These pharmacological effects are related to phytochemicals in rose petals, such as terpenes, glycosides, flavonoids, and anthocyanins (Boskabady *et al.*, 2011). On the other hand, Khaliq *et al.* reported that rose petal extract at 500 mg/ kg BW protected the kidney from gentamicin toxicity in albino rabbits (Khaliq *et al.*, 2015). Suherman *et al.* reported similar results on whether the rose petal methanol extract also had a nephroprotective effect against cadmium sulfate. These protective effects come from the antioxidant property of rose petal extract. Amiri *et al.* reported that rose petals also revealed an antioxidant effect in aluminium chloride-induced rats. All these rats improved the oxidative profile (FRAP, MDA, Catalase, and MPO) after the rose petal extract administration at 1,000 mg/kg BW. However, these previous studies are still limited to the protective effect on the kidney, and no one has yet explored the hepatoprotective effect of rose petal extract. Therefore, this study investigated the hepatoprotective effect of rose petal methanol extract in copper sulfate-induced liver injury in male Wistar rats.

## MATERIALS AND METHODS

### Study Design

This experimental study used Post-Test Only Control Group Design from October 2022 to December 2022 in Pharmacology Laboratory, Universitas Prima Indonesia. This study has been approved by Health Research Ethics Committee Universitas Prima Indonesia with letter no. 018/KEPK/UNPRI/XII/2022.

### Materials

This study used some materials, including distilled water,  $\alpha$ -naphthol, concentrated nitric acid, acetic anhydride, concentrated sulfuric acid, ethanol (distilled), mercury (II) chloride, potassium iodide, iodine, bismuth (III) nitrate, concentrated hydrochloric acid, lead (II) acetate, iron (III) chloride, 10% buffer formalin solution, isopropanol, chloroform, methanol, n-hexane, SGOT and SGPT Dialab® reagent kits, zinc powder, toluene, dyes powder (hematoxylin and eosin).

### Extraction Process

Red Rose petal was collected and washed with running water, then drained and weighed. Rose petal was dried by

a drying cabinet to form a dry rose petal simplicia and weighed it. This dry rose petal simplicia was ground to form rose petal simplicia powder and weight. The obtained rose petal simplicia powder was extracted by the maceration method. All dry simplicia powder was soaked into 98% methanol solution as the solvent in a ratio of 1:3. After that, it was filtered, and the residue was macerated again in the same way. Meanwhile, all filtrate from all filtration processes was collected to evaporate by a rotary vacuum evaporator at 50°C. Then, concentrated rose petal methanol extract was stored at 20°C. (Suhartomi *et al.*, 2020; Gulo *et al.*, 2021; Chiuman, Ginting and Yulizal, 2022)

### Phytochemicals Screening

The concentrated rose petal methanol extract underwent phytochemical screening to investigate the presence of alkaloids, saponin, flavonoids, tannin, steroids, terpenoids, and glycosides. This phytochemical screening was performed based on the modified Fansworth method. (Widowati *et al.*, 2018; Mawarni *et al.*, 2020; Chiuman *et al.*, 2023)

### Oral Suspension Formulation

This concentrated extract was suspended in 0.5% Sodium Carboxyl Methyl Cellulose (SCMC). On the other hand, other substrates included copper sulfate, quercetin, and copper sulfate suspended into 0.5% SCMC to formulate oral suspension. (Chiuman *et al.*, 2021; Mutia, Ginting and Yulizal, 2021).

### Hepatoprotective Assay

All rats were grouped into five groups, including control, standard, Rose petal Methanol Extract-1, 2, and 3, that received 0.5% SCMC, 25 mg/ kg BW of quercetin, 400 mg/kg BW, 800 mg/ kg BW, and 1,200 mg/ kg BW of rose petal methanol extract for 14 days, respectively. In the last three days, all rats received a milliliter of copper sulfate suspension orally. (Yanti *et al.*, 2011; Mutia, 2019; Mutia and Chiuman, 2019; Mutia, Ginting and Yulizal, 2021)

Furthermore, all rats were sacrificed on the 15<sup>th</sup> day by chloroform inhalation. After that, the blood was obtained by intracardiac puncture, and the liver was resected from incised abdomen wall. The obtained blood was collected in a purple blood tube (EDTA-Contained). After that, the obtained blood was separated by centrifugation at 3,000 rpm for 15 minutes. The blood was divided into two layers: serum in the upper layer and blood clot in the lower layer. The obtained serum was used for liver function tests, including SGOT and SGPT using Dyasis ® Reagen Kit. On the other hand, the obtained liver was sliced and stained by Hematoxylin and Eosin. The liver histology scoring system was described in Table 1.

**Table 1.** Liver Histology Scoring System.

Pathology changes	Description	Score
Ballooning degeneration	No Ballooning degeneration	0
	Minimal enlargement in a few hepatocytes	1
	Mild enlargement in many hepatocytes	2
	Moderate enlargement in a few hepatocytes	3
	Severe enlargement in a few hepatocytes	4
Inflammation	No inflammatory foci	0
	An inflammatory focus per 200 hpf	1
	2-4 inflammatory foci per 200 hpf	2
	> 4 inflammatory foci per 200 hpf	3
Apoptotic Cells	No apoptotic cells	0
	Few apoptotic cells	1
Fibrosis	No fibrosis	0
	Portal/ sinusoidal minimal fibrosis	1
	Portal/ sinusoidal mild fibrosis	2
	Bridging fibrosis	3
	Cirrhosis	4

**Data Analysis**

Initially, all data was described by descriptive statistics, including central tendency and dispersion. Initial body weight, SGOT, and SGPT level were described by mean and standard deviation. Meanwhile, the scoring system was described by median and Minimum to Maximal values. After that, the initial body weight, SGOT, and SGPT were analyzed by one-way ANOVA and Post Hoc Tukey HSD test.

**RESULTS AND DISCUSSION**

**Physical Characteristics and Phytochemicals Screening**

This study used 678 grams of fresh rose petals. This fresh rose petal was then dried into 495 grams rose petal simplicia powder and extracted into 55 grams of concentrated rose petal methanol extract. Thus, the yield of rose petal methanol extract was 11.11%. The obtained concentrated rose petal methanol extract then underwent a phytochemical screening and it showed some

phytochemicals, including alkaloids, saponins, flavonoids, and tannins.

**Hepatoprotective Assay**

This study used 25 male Wistar rats, and the initial body weight of these male Wistar rats was described in the following Table 2.

**Table 2.** Comparison of Initial Body Weight in All Groups.

Group	Mean	SD	P-Value
Control	192.17	7.48	
Standard	191.50	7.33	
Rose Petal Methanol Extract-1	193.50	8.02	0.958
Rose Petal Methanol Extract-2	193.50	7.01	
Rose Petal Methanol Extract--3	194.50	7.01	

Based on Table 2 that there was no significant initial body weight in all rats. It can be seen from the P-Value > 0.05 (P-Value: 0.958). These rats' initial body weight averages ranged between 191.50-194.50 grams. After that, all rats underwent a liver protection assay against the copper sulfate, and the SGOT and SGPT levels were described in Table 3.

**Table 3.** Comparison of Liver Function Test in All Groups.

Group	SGOT (IU/L)	SGPT (IU/L)
Control	265.00 ± 74.35a	242.33 ± 33.80a
Standard	121.00 ± 13.84b	125.33 ± 14.07b
Rose petal Methanol Extract-1	178.67 ± 6.71b	184.50 ± 9.40c
Rose petal Methanol Extract-2	154.17 ± 5.15b	165.17 ± 3.76cd
Rose petal Methanol Extract--3	140.83 ± 3.87b	148.50 ± 5.01bd
<b>P-Value</b>	<b>&lt; 0.05</b>	<b>&lt; 0.05</b>

Data was expressed as Mean ± SD. Different superscript in same column indicates a significant difference at P-Value < 0.05

Based on Table 3, any doses of rose petal methanol extract revealed a significant decrease in SGOT and SGPT levels compared to the control group (P-Value <

0.05). Variation of rose petal methanol extract did not significantly affect the SGOT level. However, it significantly affected the SGPT level. The higher dose of

rose petal methanol extract significantly decreases the SGPT level. Interestingly, the highest dose (1,200 mg/kg BW) of rose petal methanol extract had an effect as same

as the standard group. The comparison of the SGOT and SGPT in all groups was described in Figure 1.

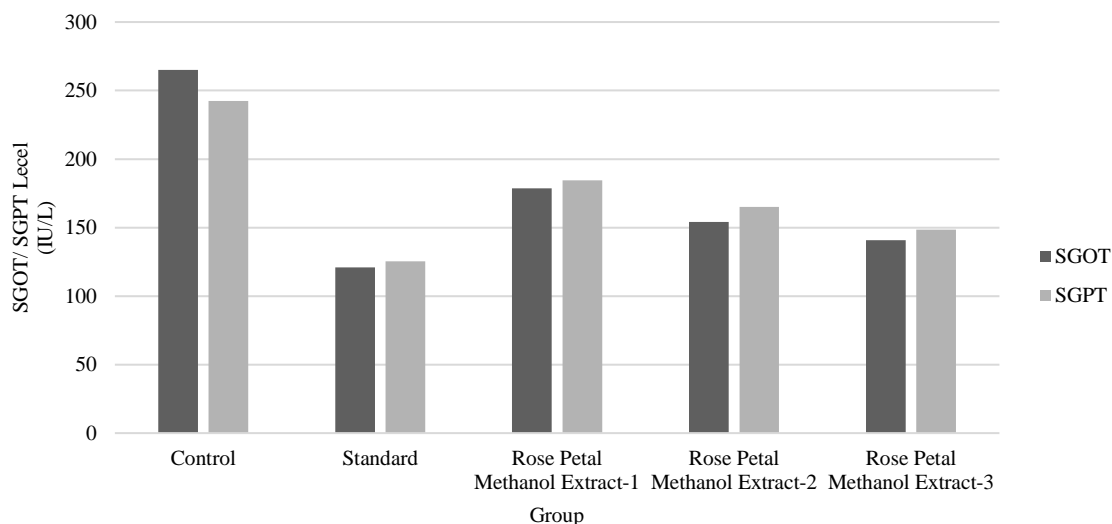


Figure 1. Bar Graph of SGOT and SGPT Level in All Groups.

Based on Figure 1, the highest level of SGOT and SGPT was found in the control group, followed by Rose Petal Methanol Extract-1, 2, and 3 groups, and the lowest level was found in the Standard group. On the other

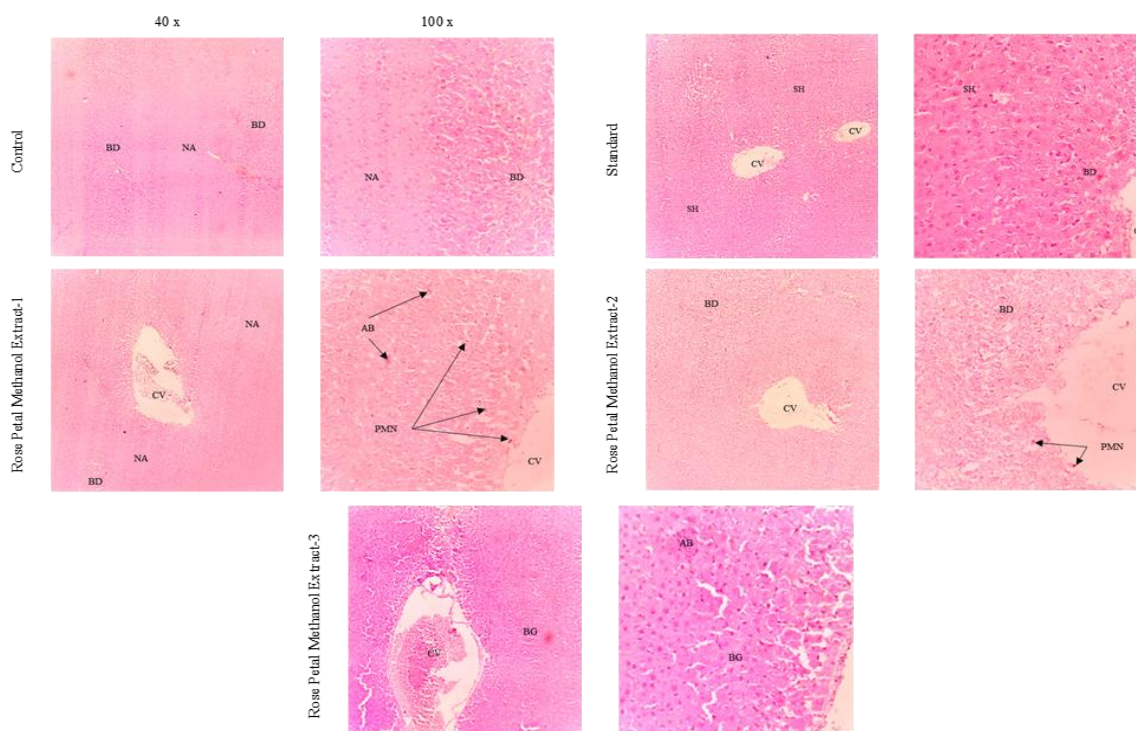
hand, this study also evaluated the histology of liver tissue in all groups, and the scoring system of liver tissue was described in Table 4.

Table 4. Liver Histology Scoring System in All Groups.

Groups	Pathology Changes				Total Score
	Ballooning Degeneration	Inflammation	Apoptotic cells	Fibrosis	
Control	2.5 (2-3)	2.00 (1-2)	1.00 (0-1)	0 (0)	5.50 (3-6)
Standard	1.00 (0-1)	0 (0)	0 (0)	0 (0)	1.00 (0-1)
Rose petal Methanol Extract-1	2.00 (1-2)	2.00 (1-2)	0 (0-1)	0 (0)	3.5 (2-5)
Rose petal Methanol Extract-2	1.50 (1-2)	1.00 (1-2)	0 (0-1)	0 (0)	3.00 (2-5)
Rose petal Methanol Extract--3	1.00 (0-2)	0.5 (0-1)	0 (0-1)	0 (0)	2.00 (0-3)

Based on Table 4, some pathology changes were evaluated in the histology of liver tissue, including ballooning degeneration, inflammation, apoptotic cell, and fibrosis. The highest total score was found in the control group, which was 5.50 (3-6), followed by the

Rose petal Methanol Extract-1 (3.5 [2-5]), 2 (3.00 [2-5]), 3 (2.00 [0-3]), and the lowest one was the standard group, that was 1.00(0.1). The lower total score indicates milder liver tissue damage than the higher total score.



**Figure 2.** Histology of Liver Tissue in All Groups. Stain: Haematoxylin and Eosin. CV: Central Vein; NA: Necrotic Area; IA: Intact Area; BD: Ballooning Degeneration; PMN: Sel Polymorphonucleate; FI: Inflammatory Foci; AB: Apoptotic Body; SH: Liver Sinusoid.

The liver histology study in all groups showed that the most severe liver damage was found in the control group. This severe damage is demarked by necrosis and ballooning degeneration. The opposite liver tissue condition was found in the standard group, which showed the mildest pathology changes. The standard group showed minimal ballooning degeneration. Meanwhile, the rose petal methanol extract showed a better liver tissue change than the control group, but it was not better than the standard group. The lowest dose (Rose petal Methanol Extract-1) of rose petal extract showed a pathology change like the control group: necrosis followed by inflammatory cell infiltration and some apoptotic cells around the central vein. The increasing rose petal extract dose improved the liver pathology changes. Rose petal Methanol Extract-2 showed milder severity of ballooning degeneration, inflammation cell infiltration, and the number of apoptotic cells. Moreover, the highest rose petal methanol extract dose showed a minimal pathology change (minimal ballooning degeneration)).

**Discussion**

This study demonstrates that rose petal methanol extract had a liver protection effect against copper in the form of copper sulfate (Cu<sub>2</sub>SO<sub>4</sub>). The decrease of SGOT and SGPT levels indicated the liver protection effects in line with the increase of rose petal extract dose (P value <0.05). On the other hand, it also supports improving liver tissue structure in histology studies. The milder

liver severity damage (ballooning degeneration and inflammation in the liver tissue) required a higher dose of rose petal extract.

Some studies have been performed to investigate the effects of excess copper intact by in vivo and observational methods. An in vivo study that used rats as trial animals reported that excess copper exposure induced cell apoptosis and increased the number of astrocytes in the hippocampus and frontal cerebral cortex, which either directly destructed the cell or induced stress pathway (glutamate and oxidative pathway). It caused memory and learning disorders. In addition, Another study reported that the excess copper in the body also accumulated in the lung tissue among 17 workers from 30 copper mining workers, and it manifested as acute alveolitis or interstitial lung inflammation (Kalita *et al.*, 2017; Jian *et al.*, 2020).

This study showed the improvement of liver tissue by SGPT and SGOT enzymes as biochemical parameters. SGPT enzyme usually catalyzes the amino group transfer reaction, including alanine and alpha-ketoglutaric acid. The highest concentration of SGPT enzyme is found in the liver tissue, and the lower concentration in other tissues. The reference value of the SGPT serum is 5-35 IU/liter. SGPT enzyme is more sensitive than SGOT. However, both enzymes increase in almost all liver diseases. Extensive SGPT elevation is associated with extensive liver tissue damage, such as fulminant viral hepatitis, toxin-induced liver injury, and prolonged circulation collapse. SGPT elevation commonly indicates

acute mild hepatitis and diffuse or localized chronic liver disease. In mild hepatitis, SGPT rapidly increases than the SGOT level. (Bastiansyah, 2012)

This study also used the SGOT enzyme, other than the SGPT enzyme, as the biochemical parameter in this study. SGOT is a mitochondrial enzyme found in the liver, heart, kidney, and brain cells. Acute tissue damage leads to an increased SGOT serum level rapidly. Acute tissue damage leads to cell lysis and causes the high release of SGOT enzyme into circulation. Thus, the highly SGOT enzyme level elevation was found predominantly in liver and myocardium tissue infraction. SGOT enzyme catalyzes the aspartate and alpha-keto glutamic acid reaction into oxaloacetate and glutamate. Other than liver tissue, SGOT enzyme is also found in red blood cells and the heart. Hence, it causes the SGOT enzyme to be less sensitive than the SGPT enzyme to detect liver tissue damage. Two isoforms of this enzyme include SGOT-1 and SGOT-2. SGOT-1 is found highly in both red blood cells and cardiac cells in the cytosol. Meanwhile, SGOT-2 is highly found in the mitochondria of hepatocytes. The reference value of this enzyme is 10-40 IU/liter. (Sacher and McPerson, 2011)

Based on the information above, SGPT is more sensitive than the SGOT enzyme to demonstrate liver tissue damage. This study revealed that either dose of rose petal methanol extract significantly decreased the SGOT and SGPT enzyme levels, indicating the liver protection effect of rose petal methanol extract. The liver protection effect is associated with phytochemicals in the rose petal methanol extract. Phytochemical screening of rose petal methanol extract showed the presence of alkaloids, saponins, flavonoids, and tannins. Flavonoid is a group of polyphenol compounds with some phenol with a hydroxyl group (OH). The hydroxyl group potentially neutralizes various free radicals in the body, one of which is copper. The hydroxyl group donates the proton (H<sup>+</sup>) ion into the unstable free radical compound. Mawarni et al. (2020) reported that rose flower extract had an antioxidant effect by the ABTS radical scavenging activity, and this antioxidant effect was described by IC<sub>50</sub> value that was 17.51 ± 1.47 µg/ml.

Previous studies have investigated various organs protection effects from another part, rose leaf, against the cadmium chloride compound. Hamza et al. (2022) reported that rose leaf methanol extract protected the liver and heart tissue from CdCl<sub>2</sub> impact by suppressing LPO activity (Lipoperoxidation) and inflammatory mediators. This liver and heart protection effect was demonstrated by decreasing liver enzyme levels, increasing antioxidant enzyme, decreasing free radical formation, and improving liver and heart structure. On the other hand, Hamza et al. also reported that the rose leaf extract has an anticancer effect on liver cancer cells (HepG2). However, the previous study reported a lower effective dose of extract, that was 400 mg/ kg BW to

showed a similar protective effect in this study (Hamza, Al-Malki, *et al.*, 2022; Hamza, Al-Yasi, *et al.*, 2022).

All treatment groups received copper as Cu<sub>2</sub>SO<sub>4</sub> orally, where the substance is toxic injury. In the histological picture of all rat liver tissue, liver damage or liver necrosis occurs around the porta hepatic area; This can be seen from the difficulty in identifying the porta hepatic area in the histological picture of the liver in each treatment group. In this study, improvement in liver histology was reflected in the reduced necrosis and ballooning degeneration areas.

All groups received copper in the form of CuSO<sub>4</sub> orally, and copper acted as a toxic substance. The copper substance induced toxic liver injury. Liver injury was classified into two pathology damage models: toxic and hypoxic. Hypoxic injury underwent pathology changes around the central-zonal area. Meanwhile, the toxic injury underwent pathology changes around the porta hepatic area. This study showed that all groups showed pathology changes around the porta hepatic area. The severity of the pathology changes showed a difference among the group. The lower dose of rose petal methanol extract showed massive pathology damage than the higher dose of rose petal methanol extract, and it was showed from challenging to identify the porta area in the lowest dose of rose petal methanol extract and control group. These pathology changes included necrosis and ballooning degeneration (Cano P., Cifuentes P. and Amariles, 2017; Mohan, 2019).

## CONCLUSIONS

Overall, it can be concluded that rose petal methanol extract could protect the liver against copper impact. The improvement of liver function test and liver tissue structure demonstrated the liver protection effect. The effective dose to show a similar protective effect to the antioxidant compound (quercetin) was 1,200 mg/ kg BW.

**Acknowledgements:** This study was supported by Faculty of Medicine, Universitas Prima Indonesia.

**Authors' Contributions:** *Conceptualization:* Caroline Febrina Hutagalung, Ermi Girsang, Maya Sari Mutia; *Methodology:* Caroline Febrina Hutagalung, Ermi Girsang; *Investigation:* Caroline Febrina Hutagalung; *Discussion of results:* Caroline Febrina Hutagalung; *Writing – Original Draft:* Caroline Febrina Hutagalung; *Writing – Review and Editing:* Suhartina, Oliviti Natali; *Supervision:* Ermi Girsang, Maya Sari Mutia; *Approval of the final text:* Caroline Febrina Hutagalung, Ermi Girsang, Maya Sari Mutia.

**Competing Interests:** The authors declare no competing interests.

**Funding:** This study did not receive any funding.

## REFERENCES

- Bastiansyah, E. (2012) Panduan Lengkap Membaca Hasil Tes Kesehatan. Jakarta: Penebar Plus.
- Boskabady, M. H. et al. (2011) "Pharmacological effects of *Rosa damascena*," Iranian Journal of Basic Medical Sciences, 14(4), pp. 295–307. doi: 10.22038/ijbms.2011.5018.
- Cano P., A., Cifuentes P., L. and Amariles, P. (2017) "Structured literature review of hepatic toxicity caused by medicines," Revista Colombiana de Gastroenterologia, 32(4), pp. 337–348. doi: 10.22516/25007440.177.
- Chiuman, L. et al. (2021) "Improvement of Liver Function from Lemon Pepper Fruit Ethanol Extract in Streptozotocin-Induced Wistar Rats," in 2021 IEEE International Conference on Health, Instrumentation & Measurement, and Natural Sciences (InHeNce). Medan, Indonesia: IEEE. doi: 10.1109/InHeNce52833.2021.9537284.
- Chiuman, L. et al. (2023) "In Vitro Study of Antibacterial Activity of Snake Fruit Extract against Extended Spectrum Beta Lactamase (ESBL) *Escherichia coli*," Jurnal Aisyah: Jurnal Ilmu Kesehatan, 8(2), pp. 715–720. doi: 10.30604/jika.v8i2.1962.
- Chiuman, L., Ginting, C. N. and Yulizal, O. K. (2022) "Lemon Pepper Extract Improves Diabetic Nephropathy in Diabetic Rats," Open Access Macedonian Journal of Medical Sciences, 10(A), pp. 170–175. doi: 10.3889/oamjms.2022.8226.
- Chubaka, C. E. et al. (2018) "Lead, zinc, copper, and cadmium content of water from South Australian rainwater tanks," International Journal of Environmental Research and Public Health, 15(7), pp. 1–12. doi: 10.3390/ijerph15071551.
- Gafur, N. A. et al. (2018) "A case study of heavy metal pollution in water of Bone River by Artisanal Small-Scale Gold Mine Activities in Eastern Part of Gorontalo, Indonesia," Water (Switzerland). doi: 10.3390/w10111507.
- Gulo, K. N. et al. (2021) "Antioxidant Activity of Flavonoid Compounds in Ethanol and Ethyl Acetate Extract from Citrus Sinensis," in AIMS 2021 - International Conference on Artificial Intelligence and Mechatronics Systems. IEEE, pp. 1–6. doi: 10.1109/AIMS52415.2021.9466078.
- Hamza, R. Z., Al-Malki, N. A., et al. (2022) "Chemical Characterization of Taif Rose (*Rosa damascena*) Methanolic Extract and Its Physiological Effect on Liver Functions, Blood Indices, Antioxidant Capacity, and Heart Vitality against Cadmium Chloride Toxicity," Antioxidants, 11(1229), pp. 1–17. doi: 10.3390/antiox11071229.
- Hamza, R. Z., Al-Yasi, H. M., et al. (2022) "Chemical Characterization of Taif Rose (*Rosa damascena* Mill var. *trigintipetala*) Waste Methanolic Extract and Its Hepatoprotective and Antioxidant Effects against Cadmium Chloride ( $\text{CdCl}_2$ )-Induced Hepatotoxicity and Potential Anticancer Activities against," Crystals, 12(460), pp. 1–20. doi: 10.3390/cryst12040460.
- Jian, Z. et al. (2020) "Oxidative stress, apoptosis and inflammatory responses involved in copper-induced pulmonary toxicity in mice," Aging, 12(17), pp. 16867–16886. doi: 10.18632/AGING.103585.
- Kalita, J. et al. (2017) Memory and Learning Dysfunction Following Copper Toxicity: Biochemical and Immunohistochemical Basis, Molecular neurobiology. doi: 10.1007/s12035-017-0619-y.
- Khalik, T. et al. (2015) "Nephroprotective Potential of *Rosa damascena* mill Flowers, *Cichorium intybus* Linn Roots and Their Mixtures on Gentamicin-Induced Toxicity in Albino Rabbits," Pakistan Veterinary Journal, 35(1), pp. 43–47.
- Mawarni, E. et al. (2020) "Antioxidant and Elastase Inhibitor Potential of Petals and Receptacle of Rose Flower (*Rosa damascena*)," Pharmaceutical Sciences and Research, 7(2), pp. 105–113. doi: 10.7454/psr.v7i2.1016.
- Mohan, H. (2019) Textbook of Pathology Eighth Edition. New Delhi: Jaypee.
- Mutia, M. S. (2019) "Histology Study of Liver Changes Paracetamol-Induced Wistar Rats Treated with Sunkist (*Citrus sinensis* L. Osbeck) Extract," American Scientific Research Journal for Engineering, Technology, and Science, 59(1), pp. 1–7.
- Mutia, M. S. and Chiuman, L. (2019) "Efek Hepatoprotektif Ekstrak Etanol *Citrus sinensis* L. Osbeck pada Tikus yang Diinduksi Parasetamol [Hepatoprotective Effect of Citrus sinensis (L.) Osbeck Ethanol Extract in Paracetamol-Induced Rats]," Majalah Kedokteran Bandung, 51(4), pp. 189–193.
- Mutia, M. S., Ginting, C. N. and Yulizal, O. (2021) "Sunkist Peel Ethanol Extract Ameliorates Diabetic Nephropathy in Streptozotocin-Induced Diabetic Wistar Rats," Open Access Macedonian Journal of Medical Sciences, 9(A), pp. 1086–1091.
- Nizami, G. and Rehman, S. (2018) "Assessment of heavy metals and their effects on quality of water of rivers of Uttar Pradesh, India: A review," J Environ Chem Toxicol, 2(2), pp. 65–71.
- Sacher, R. A. and McPerson, R. A. (2011) Tinjauan Klinis Hasil Pemeriksaan Laboratorium. Jakarta: EGC.
- Septiono, M. A. and Roosmini, D. (2015) "Heavy Metal Distribution in Water, Sediment, and Fish at Upper Citarum River and Its Potential Exposure Pathway to Human," in Environmental Technology & Management Conference. Bandung, pp. 1–10.
- Suhartomi et al. (2020) "Antioxidant Properties of Sweet Orange Peels in Several Fractions of Methanolic Extract," in Proceedings of the International Conference on Health Informatics and Medical Application Technology - Volume 1: ICHIMAT. Medan: Scitepress Digital Library, pp. 371–378. doi: 10.5220/0009515503710378.
- Widowati, W. et al. (2018) "Antioxidant and antiaging activities of Jasminum sambac extract, and its compounds," Journal of Reports in Pharmaceutical Sciences, 7(3), pp. 270–285.
- Wilson, L. (2012) Toxic Metals and Human Health, Eck Institute Nutrition and Bioenergetics. Mexico: Eck Institute Nutrition and Bioenergetics.
- Yanti et al. (2011) "Lemon Pepper Fruit Extract (*Zanthoxylum acanthopodium* DC.) Suppresses the Expression of Inflammatory Mediators in Lipopolysaccharide-Induced Macrophages In Vitro," American Journal of Biochemistry and Biotechnology, 7(4), pp. 190–195. doi: 10.3844/ajbbbsp.2011.190.195.